

Landesbibliothek Oldenburg

Digitalisierung von Drucken

Disputationes Chirurgicæ Selectæ

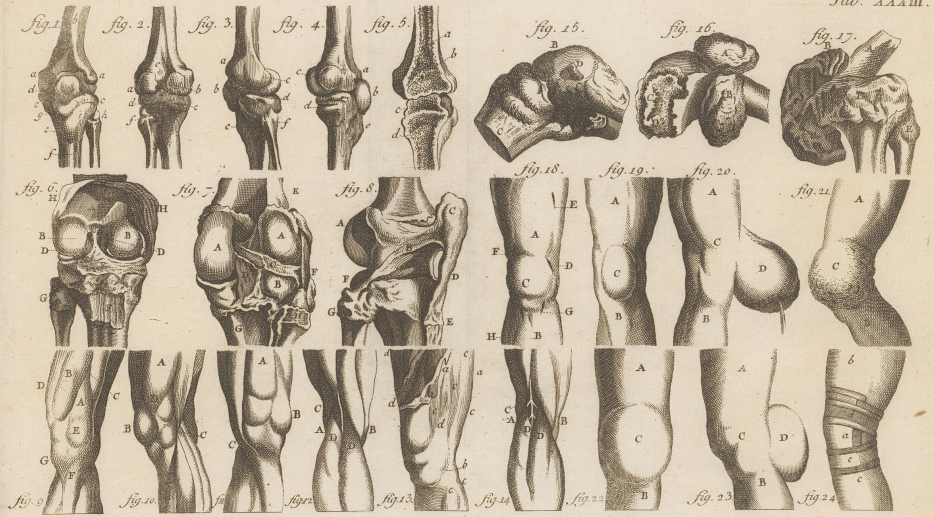
Haller, Albrecht von


Lausannæ, MDCCLV.

VD18 90538943

Illustration: Tab. XXXIII. Disp. Chirurg. Tom. IV. Heister De Genuum Morbis.

urn:nbn:de:gbv:45:1-16605





anxiosi laborantem.

Fig. 2. exhibet eandem
manum à parte anteriori sive vola.

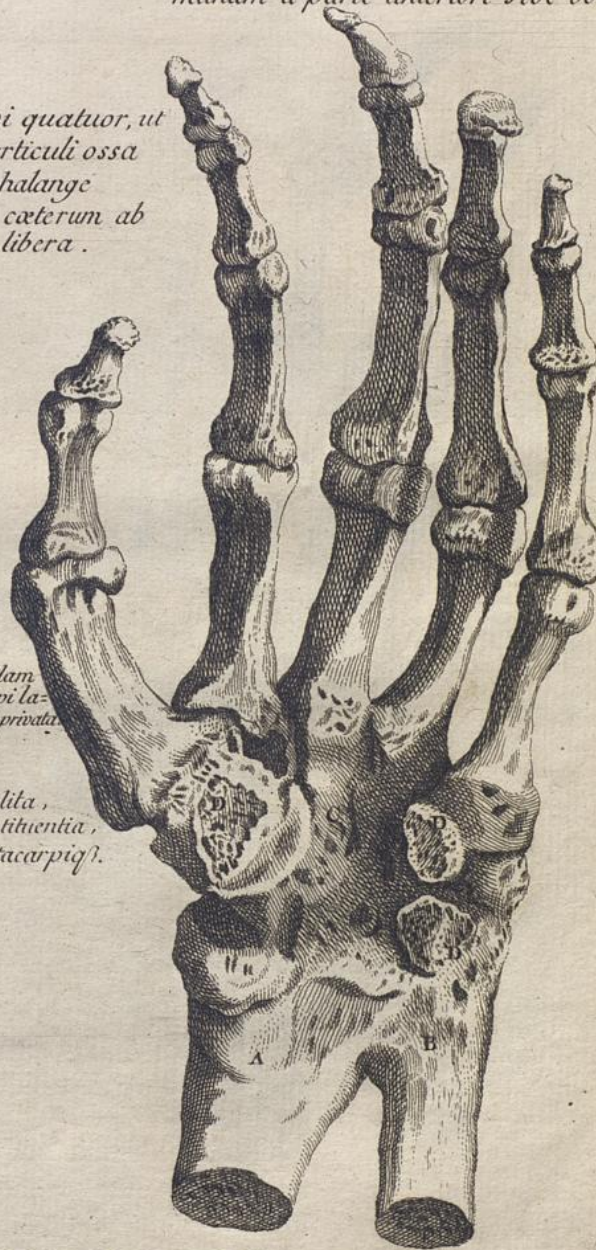carpi quatuor, ut
cis articuli ossa
ta, phalange
m in caeterum ab
nte libera.



quedam
a carpi la-
vitaeprivata

i, coalita,
constituentia,
na metacarpis.

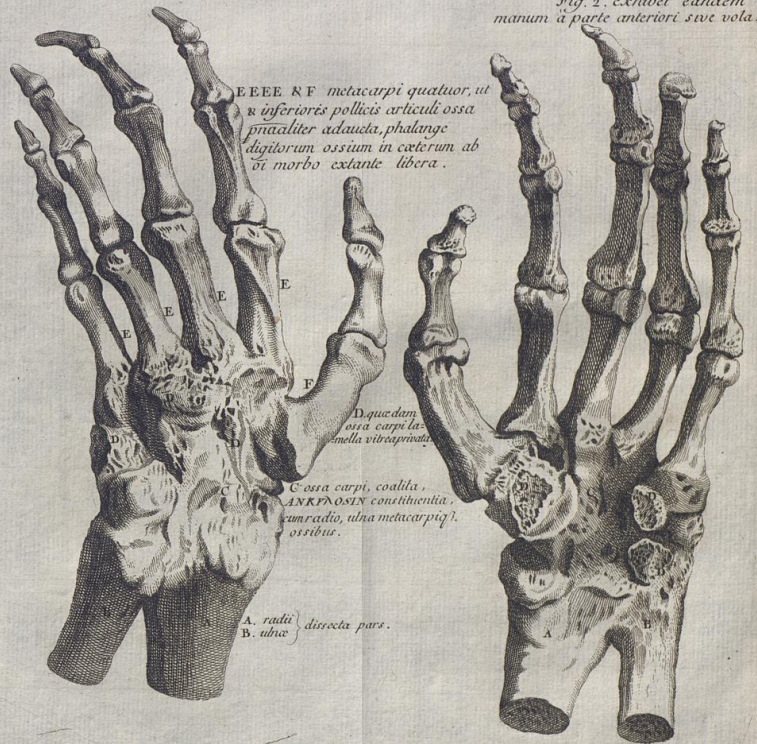ars.



LER DE ANKYLOSI. pag. 543.

Fig. 1. exhibet manum à parte postica anglosi laborantem.

Fig. 2. exhibet eandem manum à parte anteriori sive vola.



EEEE & F metacarpi quatuor, ut
 & inferiores pollicis articuli ossa
 p̄ncipaliter adhaerēta, phalange
 digitorum ossium in ceterum ab
 si morbo extante libera.

D quaedam
 ossa carpi
 in sella vitæ carpiata

C ossa carpi, coacta,
 ANKYLOSIN constituenta,
 cum radio, ulna metacarpiq̄
 ossibus.

A. radii } dissecta pars.
 B. ulnae }

Disp. Chirurg. Tom. IV. MÜLLER DE ANKYLOSI. pag. 543.